

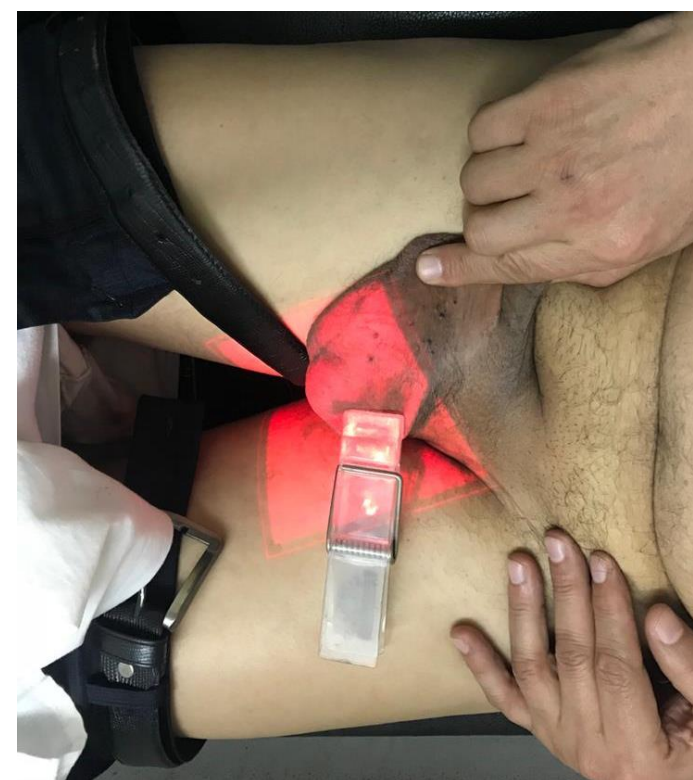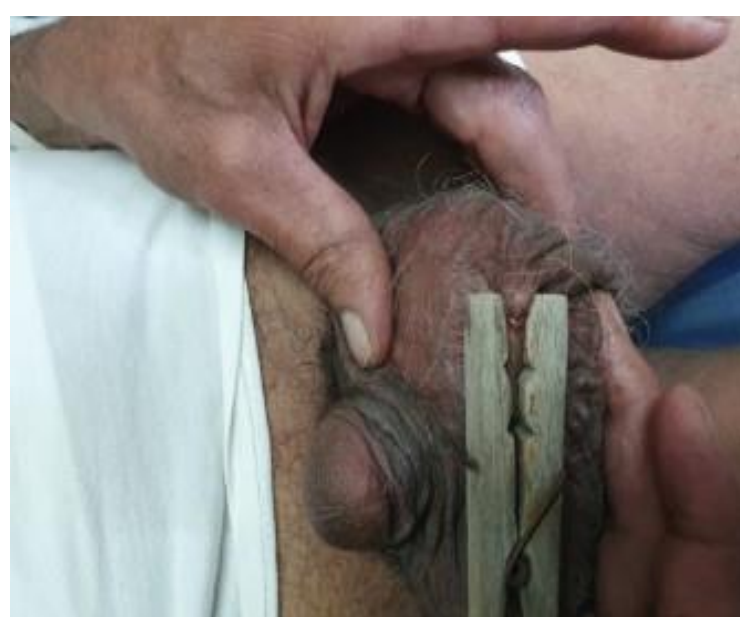**Aim**

To present a method of Control of emergency spontaneous scrotal angiokeratoma bleeding in a sensitive area from multiple Lesions, superficial blood Vessels, no tissue support and difficult compression using sclerotherapy and good visualization of bleeding source.

**First Aid Management**

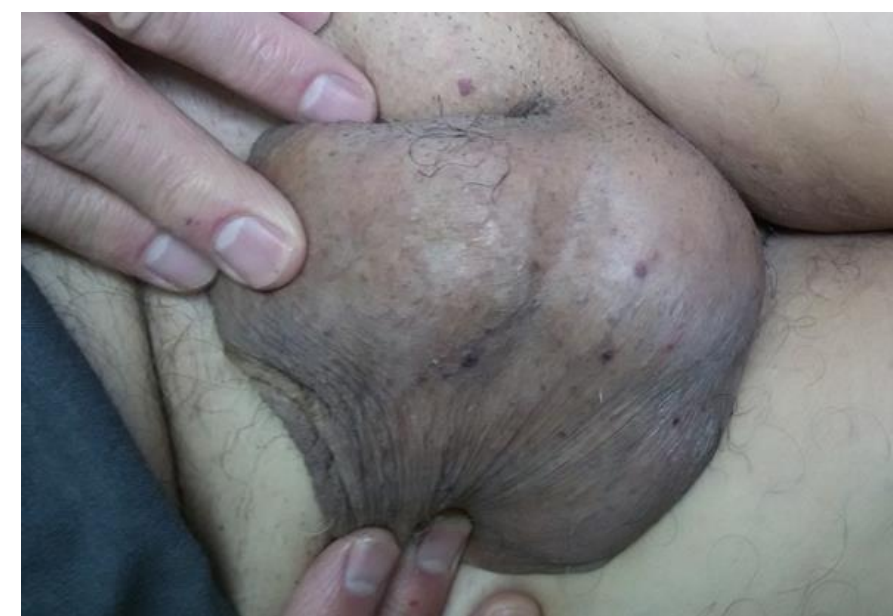1-Direct hand compression .

2-Clothespin

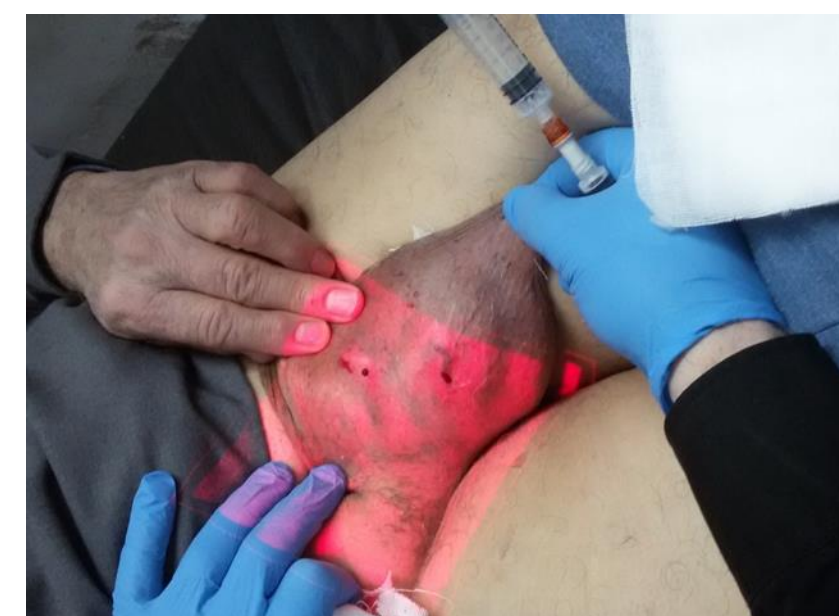

**METHODS**

Twenty male Patients( age ranged between 38 – 60 years) with previously mentioned lesions. 0.5-1% foam polidocanol using easy foam kit and AccuVein AV400 infrared Laser for accurate injection and clinical follow up.



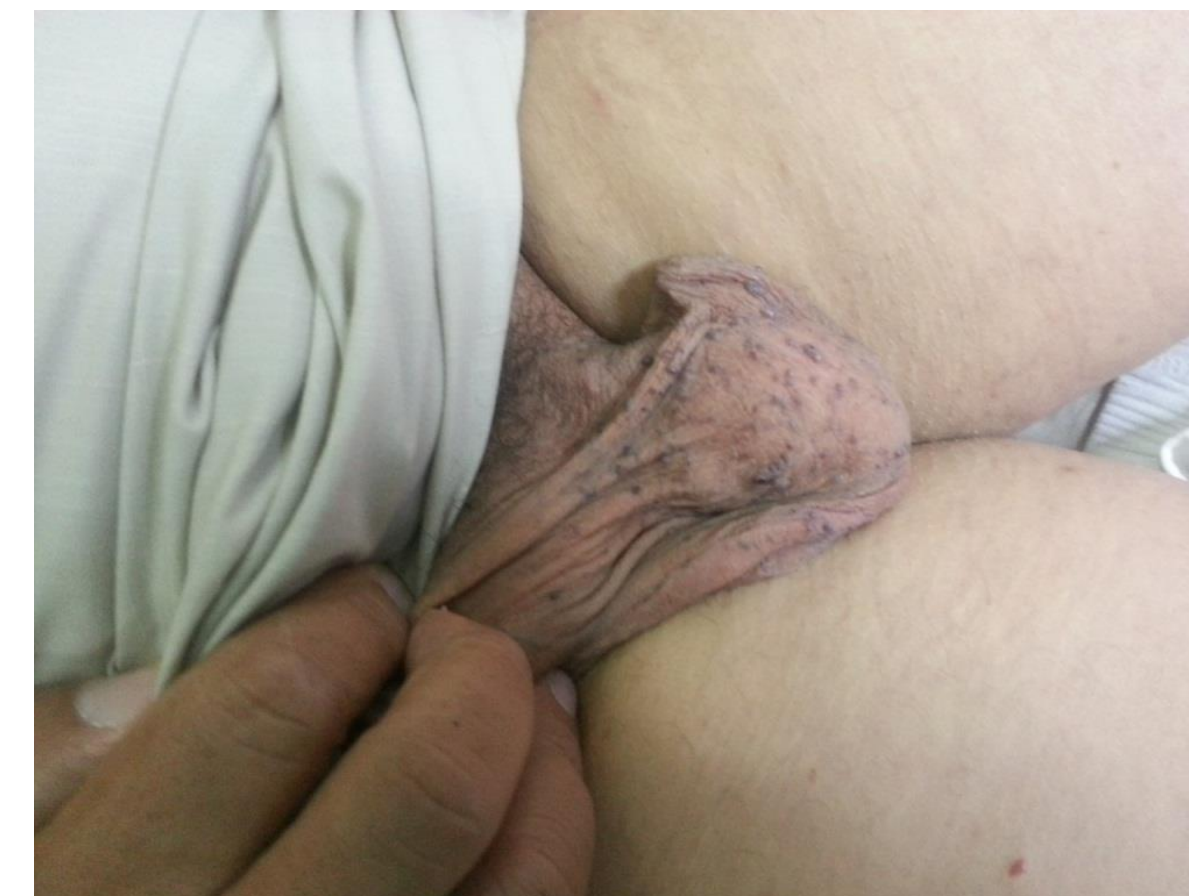
Difficult lesion &feeder visualization



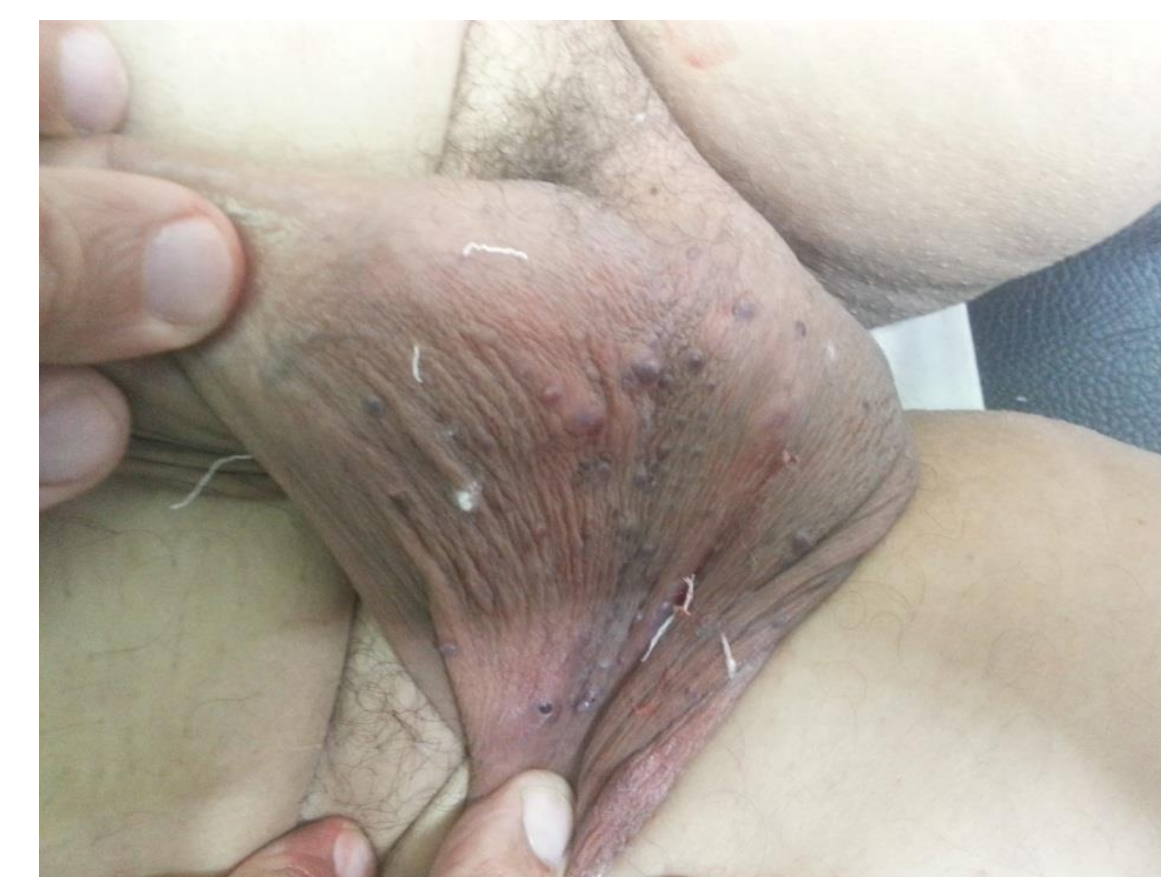Easy lesion &feeder visualization By Accuvein

**RESULTS**

All patients were successfully treated with foam Sclerotherapy in three sessions of the lesions without any further recurrence over one year of follow-up



Post



**RESULTS**

**CONCLUSION**

Foam sclerotherapy with Polidocanol by help of Nontouch infrared laser (AccuVein AV400) to visualize reticular veins in dark scrotal skin is an effective, simple, convenient, economical and safe modality for the treatment of bleeding angiokeratoma of scrotum allowing the material to treat large surface area of bleeding and potentially bleeding.